



Intervertebral disc disease (IVDD): Instructions for radiography according to the Swedish Kennel Club protocol

By: Anu Lappalainen

General instructions:

- The dog must be sedated for the radiography and the microchip must be checked.
- The radiographs must be marked permanently (e.g. lead tape) with the dog's registration number or microchip number and the date of the radiography. The side marking is mandatory in the ventrodorsal projection.

Radiographs:

In all images the spine must be parallel to the table without rotation of the spine. Use foam rubber supports (Figure 1). **All disc spaces must be clearly visible.**

At least 5 radiographs are needed:

- 1) Lateral cervical spine (**C1-C7**) (Figure 2). The front limbs are pulled back. Centering in the midcervical spine.
- 2) Lateral cervico-thoracic junction (Figure 3). Centering int the C-T junction.
- 3) Lateral thoracic spine = **C7 – L1** covered preferably in one image (Figure 4).
- 4) Lateral thoracic-lumbar junction (Figure 5). Centering int the T-L junction.
- 5) Lateral lumbar spine = **T13 – Cd1** covered preferably in one image (Figure 6). If this is not possible,two radiographs are made (T13 – L7 and L5 – Cd 1). The cranial border of the iliac bones can beused as a land mark for identification of the vertebrae.



Figure 1 Positioning

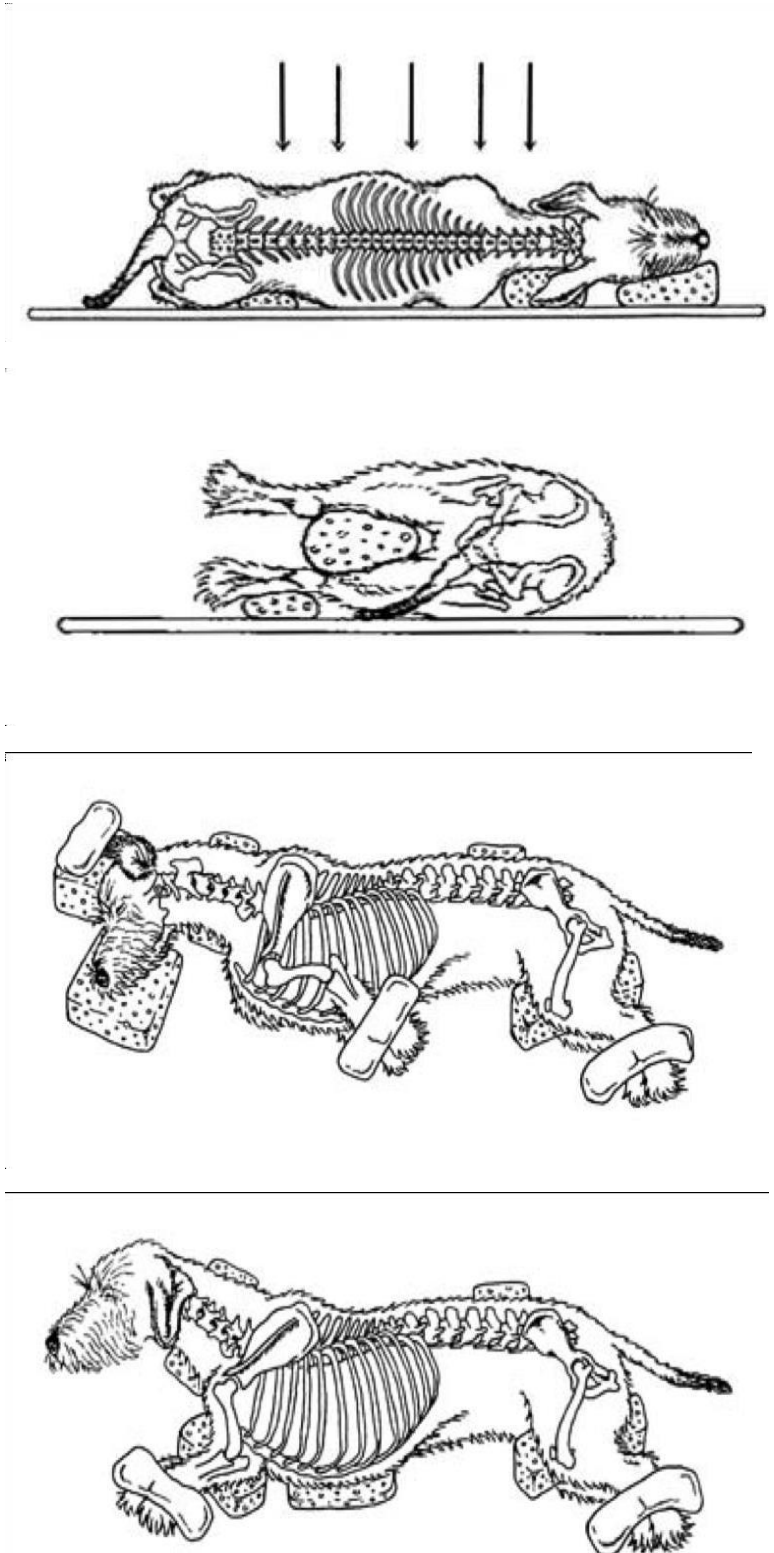




Figure 2 Cervical spine

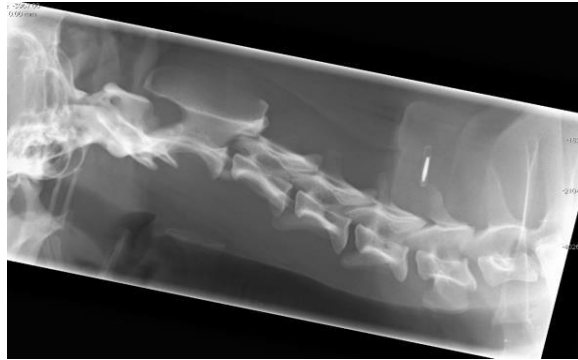


Figure 3 C-T junction

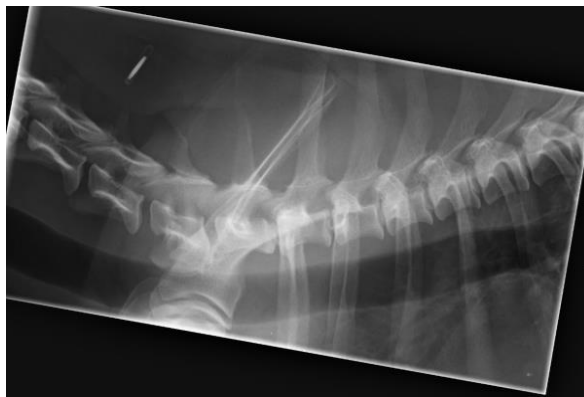

Figure 4 Thoracic spine

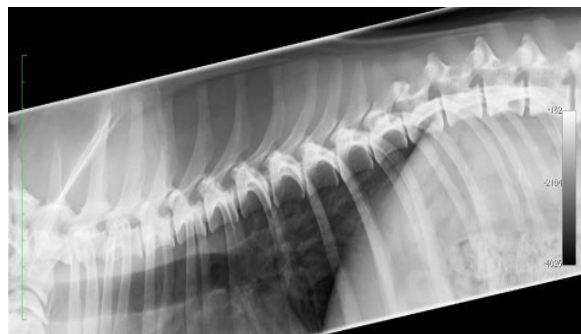
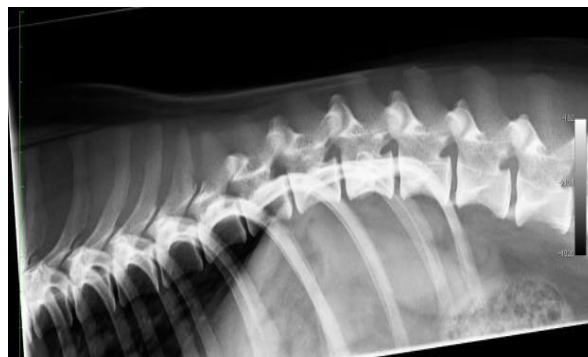

Figure 5 T – L junction





SVENSKA KENNELKLUBBEN

HUNDÄGARNAS RIKSORGANISATION

Figure 6 Lumbar spine

